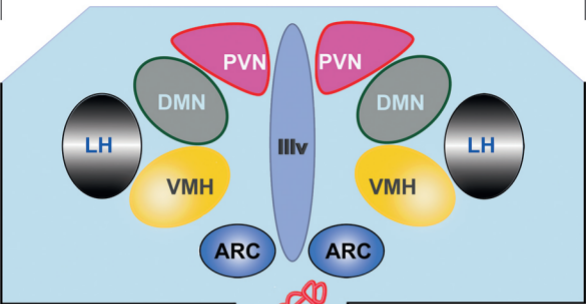
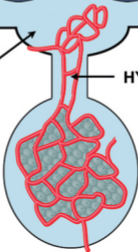


# HYPOTHALAMUS



MEDIAN  
EMINENCE

HYPOPHYSEAL PORTAL  
VESSELS

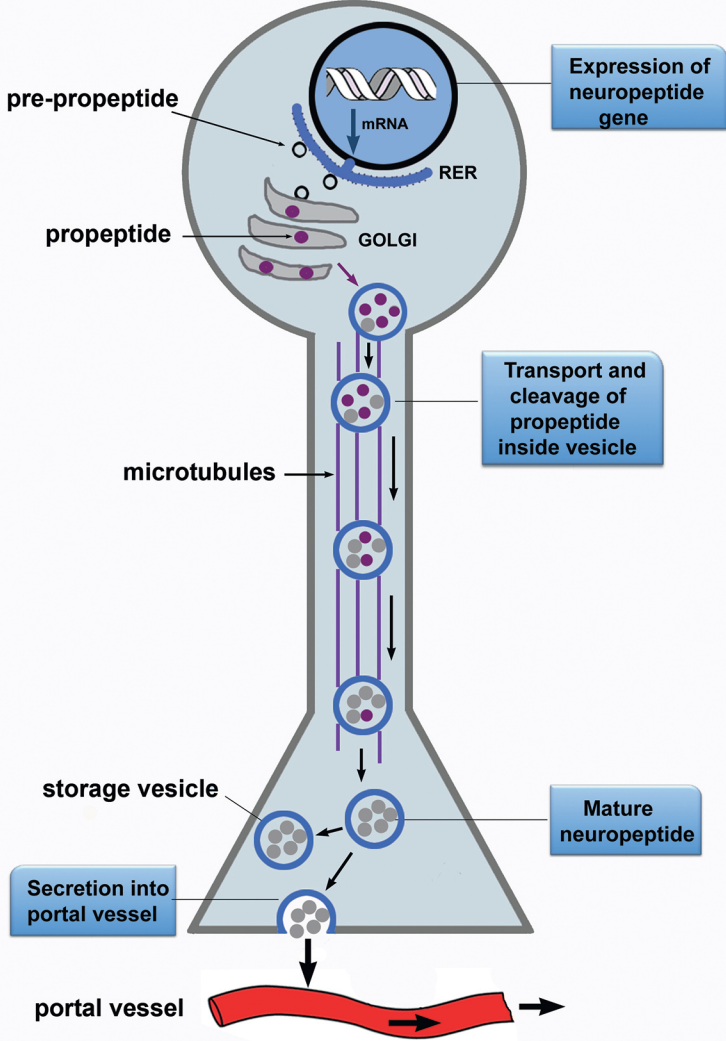


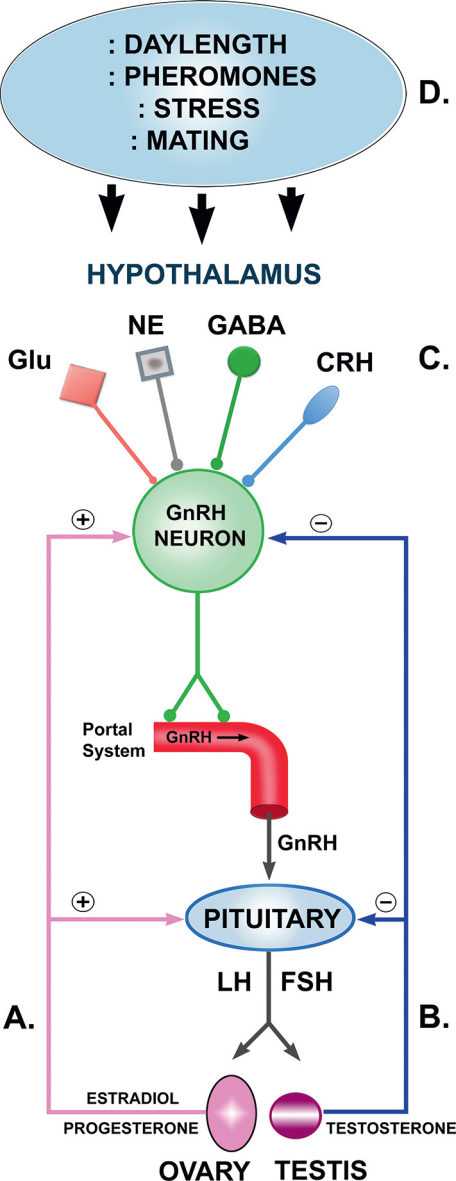
ANTERIOR PITUITARY GLAND

CELL BODY

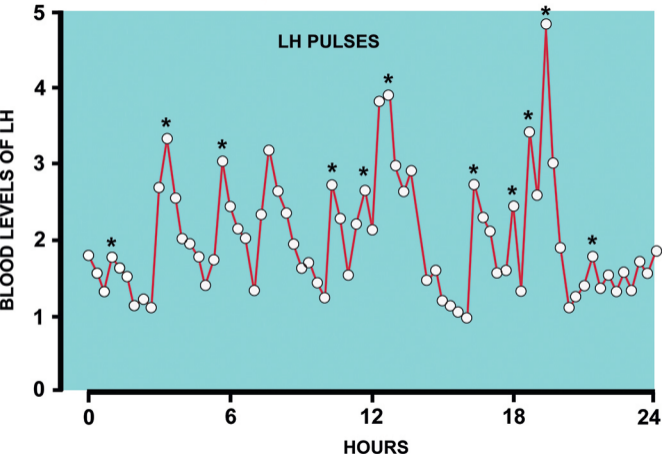
AXON

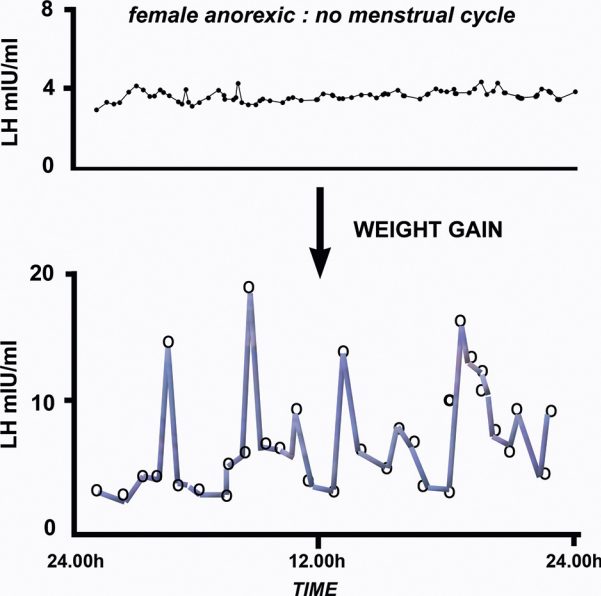
TERMINAL

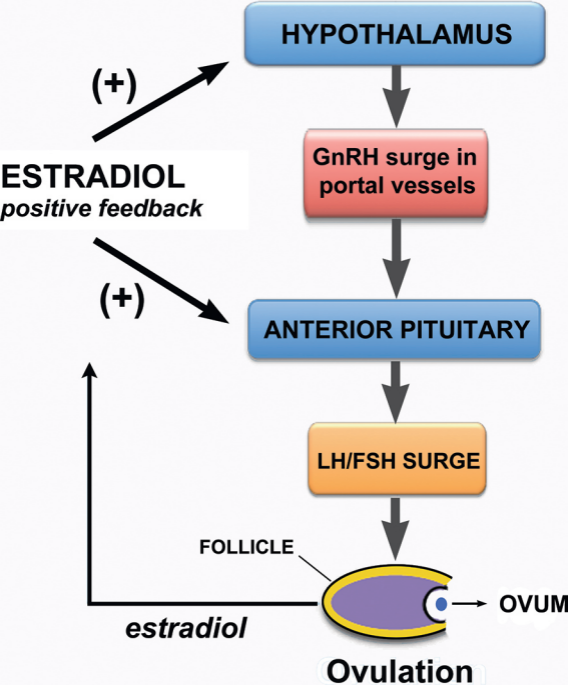




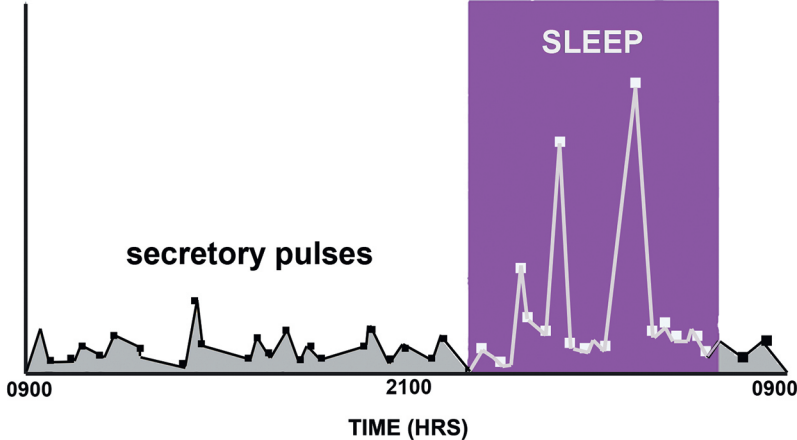
# NORMAL MALE

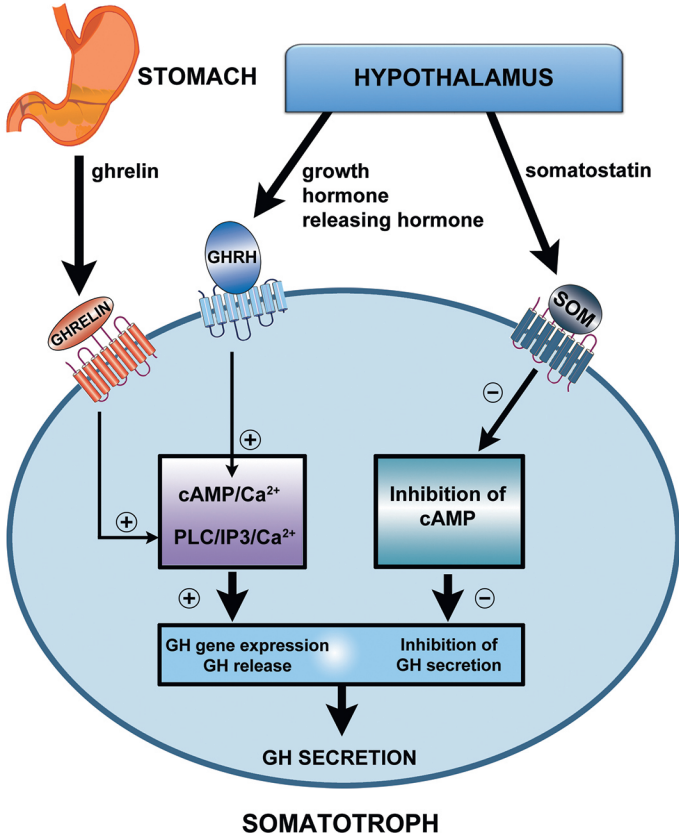




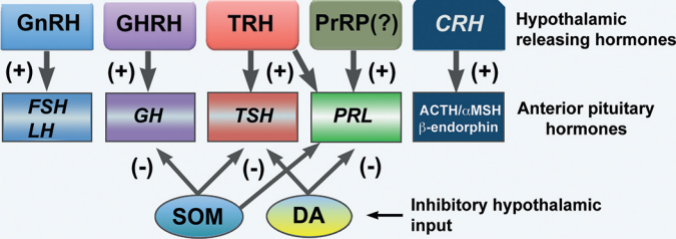


**Blood levels of GH**









# NEGATIVE FEEDBACK

